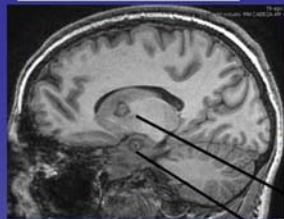
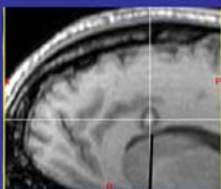


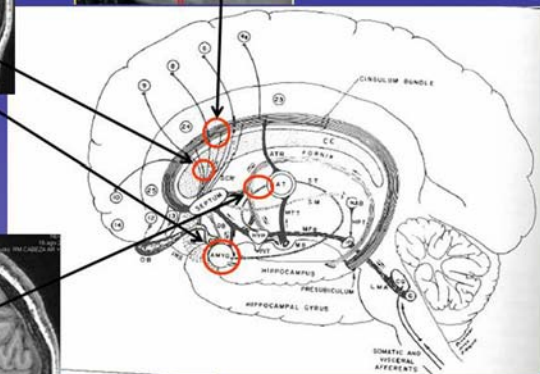
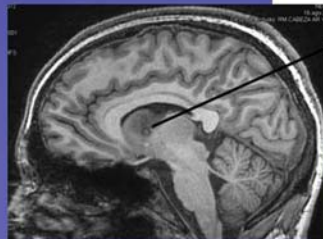
Capsulotomía anterior



Cingulotomía

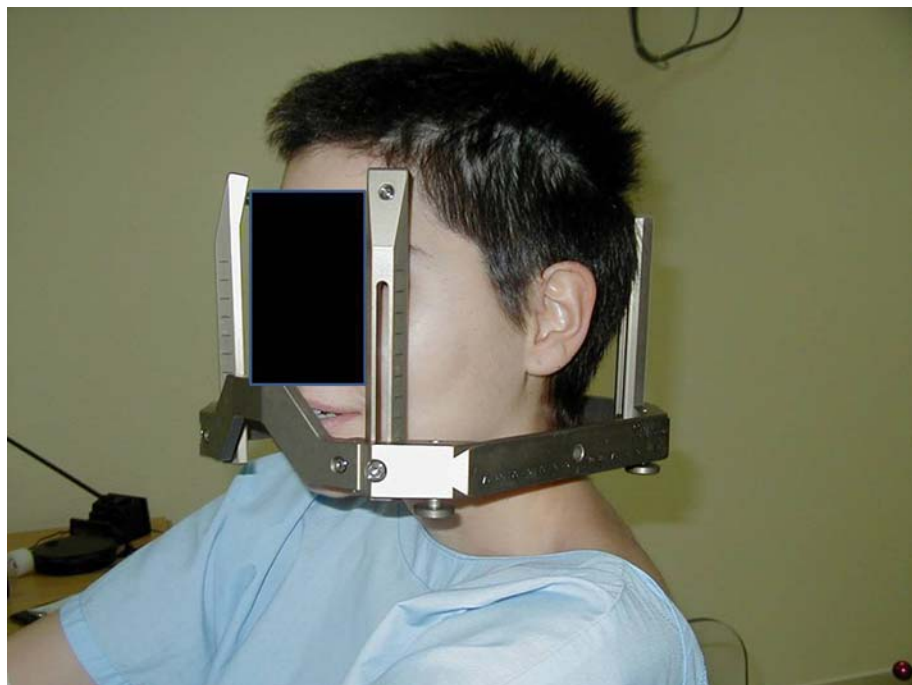

Amigdalotomía

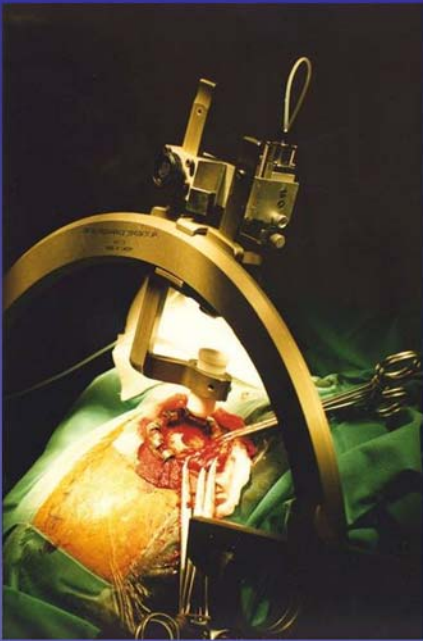
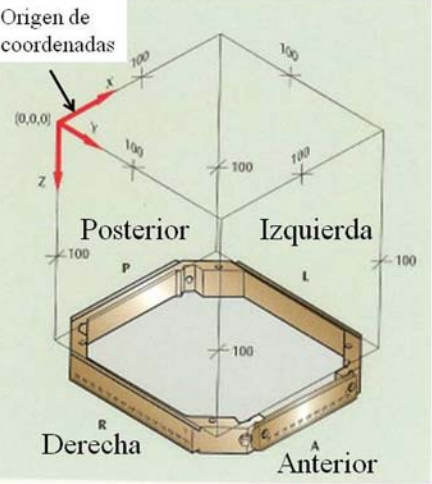
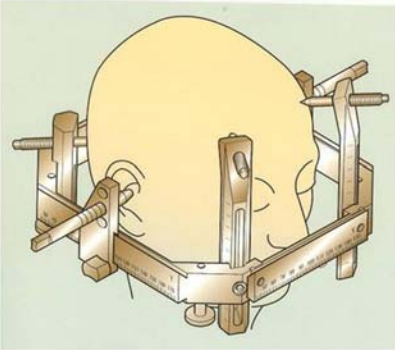


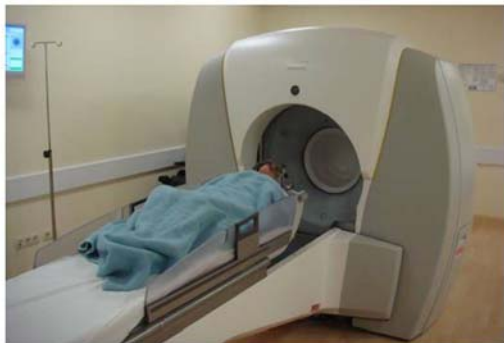estria terminal

Lesiones en el sistema límbico

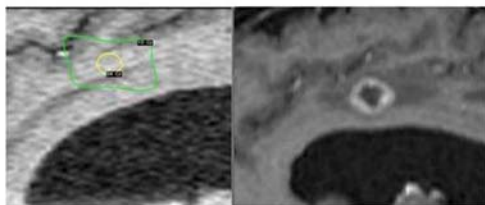


Sistema estereotactico de Leksell®



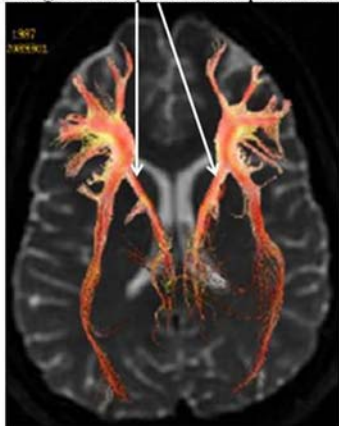


Gamma Knife Perfection

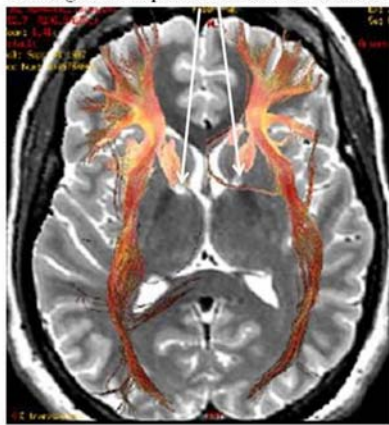

Cingulotomía: Planificación y lesión en RM pasados 9 meses

Tractografía : Capsula interna parte medial



Tractografía: Capsulotomía anterior bilateral



RM+tractografía: Capsulotomía bilateral (c) y lesión de la estria terminal (st)

